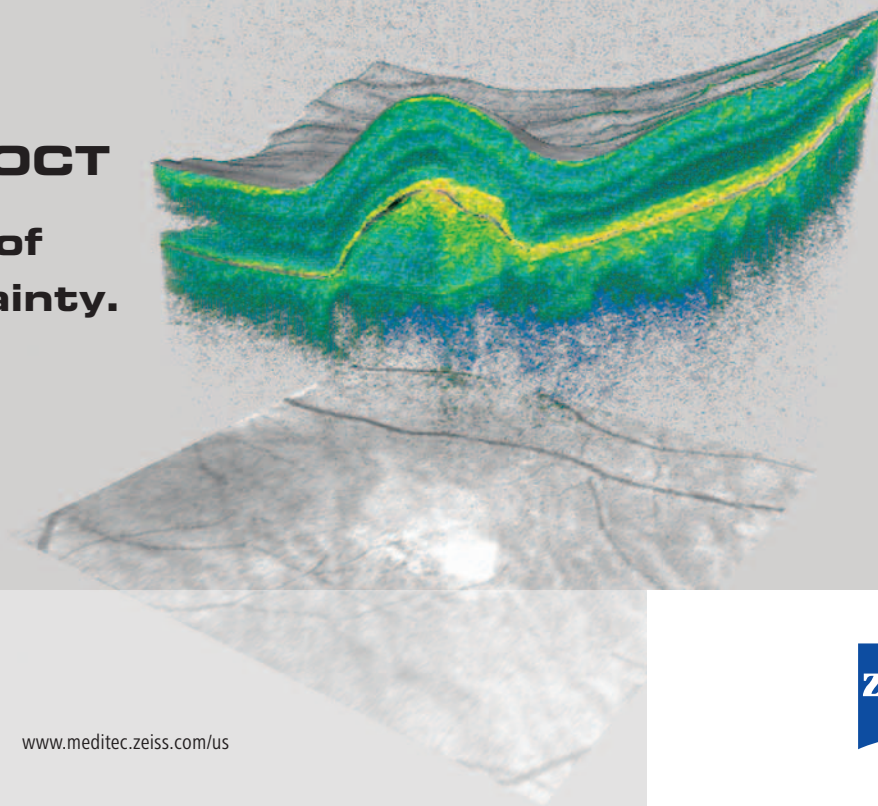
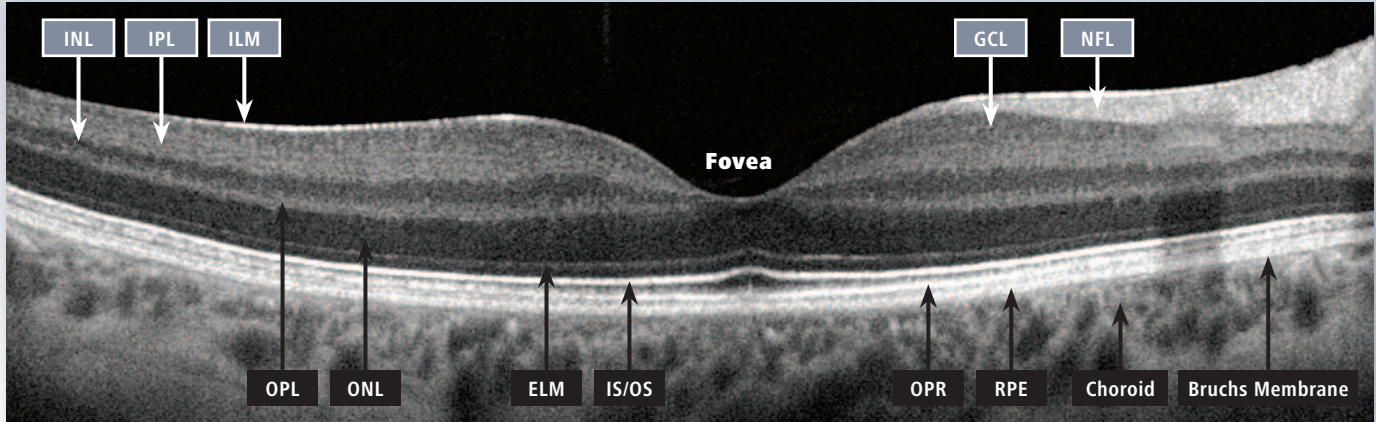


Cirrus HD-OCT

**A new level of
clinical certainty.**



Cirrus™ HD-OCT: interpretation of retinal layers



ILM: Inner limiting membrane
IPL: Inner plexiform layer
INL: Inner nuclear layer
OPL: Outer plexiform layer
ONL: Outer nuclear layer

ELM: External limiting membrane
IS/OS: Junction of inner and outer
photoreceptor segments
OPR: Outer segment PR/RPE complex

NFL: Nerve fiber layer
GCL: Ganglion cell layer
RPE: Retinal pigment epithelium
+ Bruch's Membrane